

## The Clinical and Histological Skin Changes After the Cupping Therapy (Al-Hijamah)

Kadhim Qasim Ali Al-Rubaye,\* MSc, PhD

Address: \*Department of Dermatology, College of Medicine. Basra University, Iraq

E-mail: kadhim1000@yahoo.com

\* Corresponding Author: Kadhim Qasim Ali Al-Rubaye MSc. PhD. Head of the Department of Dermatology, Basra General Hospital, Iraq

Published:

J Turk Acad Dermatol 2012; 6 (1): 1261a1.

This article is available from: <http://www.jtad.org/2012/1/jtad1261a1.pdf>

Key Words: Cupping Therapy, Al-Hijamah

### Abstract

[www.hijamacups.com](http://www.hijamacups.com)

**Background:** Cupping Therapy (CT) has been reported as treatment for several skin conditions such as acne, post herpetic neuralgia, psoriasis, atopic dermatitis and urticaria. Although it is often considered as part of the Traditional Chinese Medicine (TCM), it has been widely practiced in the Middle East and the rest of the world for centuries. In Basra, a city in the southern part of Iraq, cupping therapy is often used by alternative medicine practitioners for treating skin disorders. However, limited is known about the clinical and histological effects of cupping therapy on the skin.

**Objectives:** To investigate the immediate and delayed effect of CT on the skin, clinically and histologically.

**Material and Methods:** We visited alternative and herbal medicine clinics that practice cupping therapy in Basra. Questionnaires were given to the patients and the alternative medicine practitioners to explore their experience with cupping therapy in terms of the presenting complaints and symptoms following therapy. The different types of application techniques and the immediate and delayed clinical changes on the skin following cupping therapy have been recorded. Ten skin biopsies were taken from male participants to investigate the histological changes in the application sites.

**Results:** One hundred and thirty five patients were enrolled in the study. Of them, 102 (75.6%) were males and 33 (24.4 %) were females. The presenting complaints in males were back pain (29.4 %), Sciatica pain (15.7%) then headache (12.7%). In females, the presenting complaints were frozen shoulder (30.3%), back pain (18.2%), joint pain (12.1%) and gynecological causes (9.1%). Skin diseases were the presenting complaints in 4.9% of the males and 3% of the females. They included psoriasis, vitiligo, and eczema. Following cupping therapy, the immediate signs were erythema, swelling, bruising, bleeding, bullae formation and sings of cutting as results of cutting the skin for bloodletting. Patients reported discomfort ranging from slight tingling sensation to severe pain. Delayed clinical effects were scars in 6% of cases and patches of post inflammatory hyper-pigmentation with or without ring of ecchymosis in 4 % of total cases 30 days after cupping therapy. In all other cases complete healing of the skin was within three weeks. No adverse events were noted in our study. Histological changes following cutting and bloodletting were mild oedema, vacuolization and longitudinal fissure as a result of cutting in the epidermis. In the dermis, histological changes were dermal oedema and bleeding in the upper and lower parts of the dermis. No cellular infiltration was noted.

**Conclusion:** Cupping therapy is associated with distinctive early and late clinical changes. However, it is safe procedure and most of these changes are reversible within three weeks. There were no adverse events as a result of the therapy. The efficacy of cupping therapy in treatment is beyond the scope of this study and further studies are needed.

**Introduction**

The Chinese have been practicing the cupping for at least three thousand years along with massage, acupuncture and Moxibustion cupping form to relieve the stagnation of Qi, believed to be the vital energy or life force, and blood, both locally and in the organs [1, 2]. Practitioners of the traditional Chinese medicine (TCM) believe that diseases are caused by stagnant or blocked Qi and that cupping is able to unblock and correct the balance in the flow of Qi, thereby restoring health [3]. In Eastern Asia, cupping is a popular alternative therapy [4, 5]. It was mentioned in the oldest recorded medical textbook, Ebers Papyrus, written in approximately 1550 BC in Egypt [6].

Complementary and Alternative Medicine (CAM) has become very popular and it has gained credibility within some biomedical health care centers [6]. Surveys showed that approximately one third of population in the UK and a slightly higher percentage in the USA have used CAM [7]. Cupping Therapy (CT) is an ancient form of CAM that has been practiced in most cultures for many conditions such as high blood pressure, infections, pains, mental disorders, heart diseases and a variety of circularly diseases, and skin disorders [6, 8].

The cupping procedure basically involves creating a small area of low air pressure next to the skin. This can be through applying a cup like device on the skin. These cups can vary in shapes from balls to bells, and may

range in size from 1 to 3 inches (25 mm – 75 mm) across the opening. Plastic and glass are the most common materials used today, replacing the horn, pottery, bronze and bamboo cups used in earlier times. The low air pressure required may be created by heating the cup or the air inside it with an open flame or a bath in hot scented oils, then placing it against the skin. As the air inside the cup cools, it shrinks in size and draws the skin slightly inside. More recently, a mechanical suction pump is connected to a one way valve located at the top of the cup. Rubber cups are also available that squeeze the air out and adapt to uneven or bony surfaces [8].

In practice, cups are normally used only on softer tissue that can form a good seal with the edge of the cup. A one big cup or few cups may be used to cover a larger area. They may be used by themselves or placed over an acupuncture needle. Skin may be lubricated, allowing the cup to move across the skin slowly. The skin may be lanced before placing the cup so that the vacuum draws fluids, primarily blood, into the cup as part of the treatment [6, 8].

The most common sites on which the cups are applied are the back, chest, abdomen, and buttock; areas of abundant muscle [5]. The cups are typically left in place for 5-10 minutes or sometimes more. The after-effects of cupping often include erythema, edema, and ecchymosis in a characteristic circular

**Table 1.** The Indications for Cupping Therapy in Males and Females

Diseases	Males	Females
	No.(%)	No (%)
Back pain	30 (29.4)	6 (18.2)
Sciatica	16 (15.7)	2 (6.1)
Headaches	13 (12.7)	2 (6.1)
Frozen shoulder	9 (8.8)	10 (30.3)
Joint pain	12 (11.8)	4 (12.1)
Skin problem	5 (4.9)	1 (3.0)
Blood pressure	7 (6.9)	1 (3.0)
Polycythemia	1 (1.0)	---
Gynaecological	---	3 (9.1)
Others	9 (8.8)	4 (12.1)

**Table 2.** Immediate and Delayed Clinical Changes After Cupping

Immediate effect	Delayed effect	Sites of cuppin
1. Multiple cuttings of skin	1. Scare of cutting skin	1. Back chest
2. Erythema	2. Bruising	2. Abdomen buttock
3. Circular ecchymosis	3. Hyperpigmentation	3. Legs
4. Swelling	4. Circular ecchymosis	4. Arms
5. Bruising and bleeding		5. Face
6. Discomfort		
7. Pain		
8. Light headache		
9. Sweating		
10. Warmth		
11. Tingling sensation		

arrangement. These bruises may take days to several weeks to subside [4, 5].

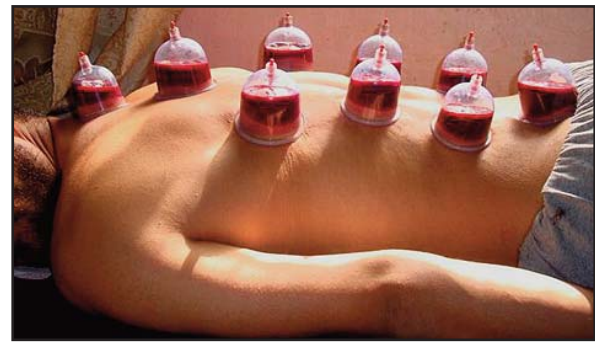
The Arabic name for cupping therapy is “Al-Hijamah” which means to reduce in size i.e. to return the body back to its natural state by the application of suction cups to the skin to draw out stagnant, congested blood and Vital Force, as well as other stagnant or morbid humors. The practice of Al-Hijamah has been part of Middle Eastern cultural practice for thousands of years [9]. Those who perform cupping therapy are called cupping therapist, traditional healer or traditional cupper.

The aims of this article are to describe skin changes (signs and symptoms) and the histological changes which result from cupping therapy.

### Materials and Methods

Part of the study included was questionnaire based. Cupping practitioners in Basra were asked to fill questionnaires to explore their experience with CT. This part also involved clinical observation of the skin changes following cupping therapy. 183 clients (125 males and 58 females) were enrolled in this study. 48 clients were excluded because of incomplete information or loss of follow up leaving 135 patients (102 males and 33 females) who completed the study. All patients were older than 18 years. An informed consent was taken prior to the study. Information sheets were given to the clients. Blood pressure, pulse rate and temperature were taken. Hemoglobin and fasting blood glucose were testes when indicated. The healer used words from the Holy Quran and Prophet Mohammed’s (May God peace and blessings be upon him) sayings such as “ The 17<sup>th</sup>, 19<sup>th</sup> or 21<sup>st</sup> day (of the Islamic, lunar month) are the best time for Al-Hijamah but avoid wednesdays and Saturdays”. The healers use their fingers and illustrated diagrams to find the right spots to place the cups avoiding bony parts and coetaneous veins. Cupping therapy equipments included a hand suction pump, 6-12 plastic cups and anti-septic wipes. All CT procedures were fully sterile. The procedure required about 20 minutes and it involved 5 phases:

1. Primary sucking. The cup is placed on the selected site. A negative pressure is created using manual suction. The cup clings to the skin and is left for a period of 3 to 5 minutes.
2. Scarification. Superficial incisions are made on the skin using 15–22 Gauge surgical blades. These incisions were 0.1 mm in depth and 0.5 cm in length in 2 or more rows each with a set of four,



**Figure 1.** The placed cup on the back skin

six, or 10 incisions all made by fully sterilized blades.

3. Bloodletting. The cup is placed back on the skin. Negative pressure is applied to collect blood in the cup (Figure 1).

4. Removal. The cup is removed, and the process is repeated 1-2 times.

5. Dressing.

It is a tradition to advise the client to fast 12 hr before the procedure and then have some dates and water. Treatments are usually scheduled every 4 to 6 months depending on the condition treated. Immediate skin changes were recorded and patients were asked to describe their experience. Patients were followed up for 30 days to monitor their skin changes. Ten Skin biopsies were taken only from male patients. The histological findings were recorded immediately after the cupping session and 3 days later.

### Results

One hundred eighty three clients (125 males and 58 females) were enrolled in this study. However, only 135 (102 males (75.6%) and 33 (24.4%) females) completed the whole study giving a participation rate of (73.8%). Clients’ ages ranged between 18-61 years of age.

Back pain was the commonest indication for cupping therapy in males (29.4% of cases) followed by sciatica and headaches in 15.7% and 12.7 % of cases respectively. In females, frozen shoulder (30.3%) was the commonest indication, followed by back pain (18.2%) and joint pain (12.1%). Skin diseases presented in 5.9% of total cases. Five cases (4.2%) were males (two cases of psoriasis, two cases of vitiligo and one case of eczema) and one case was female with psoriasis (3%) (Table 1).

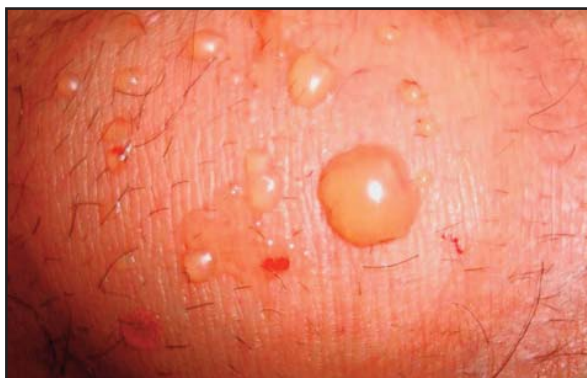Following cupping therapy, the immediate signs were erythema, swelling, bruising, blee-

ding, bullae formation (**Figure 2**) as results of cutting the skin for bloodletting. Patients reported discomfort ranging from slight tingling sensation to sever pain. Delayed clinical effects were scars in 6% of cases and patches of post inflammatory hyper-pigmentation with or without ring of ecchymosis (**Figure 3**) in 4 % of total cases 30 days post cupping therapy (**Table 2**). In all other cases complete healing of the skin was within three weeks.

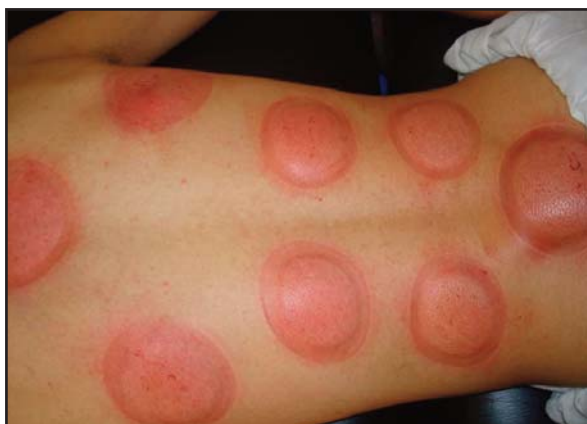Histological changes (**Figures 4, 5**) in epidermis included mild oedema, vacuolization and perpendicular breaks in the upper part of epidermis results from bloodletting procedure. In the dermis, there were upper and lower dermal oedema and bleeding with no cellular infiltration.

### Discussion

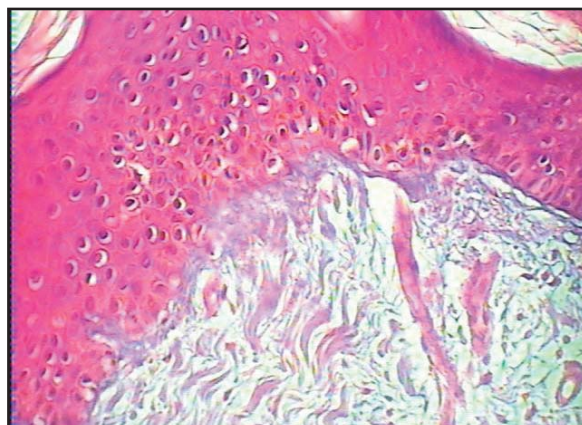
Complementary and alternative therapy (CAM) such as cupping therapy has become increasingly popular for treating skin disor-



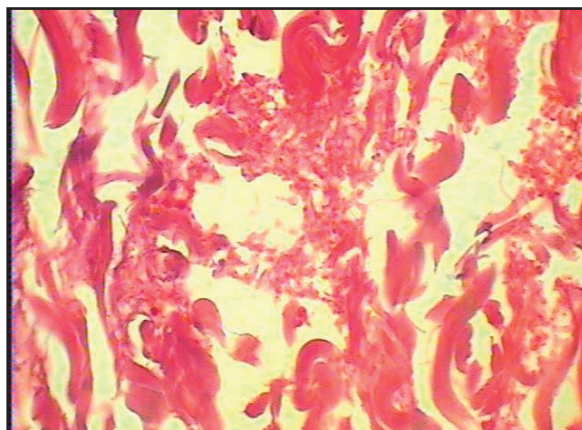
**Figure 2.** Showing the bulla formation after sucking



**Figure 3.** Red rings and ecchymoses after cupping which subside within weeks



**Figure 4.** In epidermis mild oedema and vacuolization and upper dermal oedema



**Figure 5.** Deep dermal bleeding and rupture of blood vessel

ders [10]. Yet, dermatologists are still unfamiliar with it and most of them have some misconceptions. The popularity of CAM continued to grow in developed countries such as USA, Norway during the first decade on the 21st century [11, 12, 13]. This might indicate a shift in attitude regarding CAM within the conventional health care system.

There is still some controversy around the effectiveness of cupping therapy. Few small scale studies has reported some clinical effects for wet cupping when used as an adjuvant to conventional drugs [14]. Thama et al. proposed a multi-layered finite element model in describing the behavior of the skin and underlying soft-tissue layers when subjected to cupping [15]. The skin becomes red due to the congestion of blood flow. Cupping relieves this local congestion. Cupping can be classified into three types according to the suction pressure: Light Cupping; where a weak suction is used. This is suitable for children and

elderly people. Medium Cupping: where medium pressure is used. This is possibly the commonest type of cupping. Strong Cupping where the suction is very strong and therefore it is not suitable for children and elderly people. Another classification divides cupping therapy into seven types: Moving Cupping or Massage Cupping where oil is applied to the skin and the cup is moved gently on the skin. Needle Cupping in which acupuncture is used in conjunction with cupping. Hot Cupping in which dried mugwort (*Artemisia vulgaris*) leaves, sometimes called by its oriental name Moxa, is used. Flash Cupping in which several medium cupping are performed several times in quick succession along the area being treated to stimulate it. Bleeding Cupping which is also called Full Cupping or Wet Cupping. In this procedure a surgical instrument is used to scrape the skin and the cup is then applied to collect blood. Herbal Cupping in which herbal tincture is applied onto the cup before suction. Finally, water Cupping which is the least practiced method. It involves filling a third of the cup with warm water [6, 8].

CT can be divided into two broad categories: Dry Cupping Therapy (DCT) and Wet Cupping Therapy (WCT). DCT Therapy tends to be practiced more commonly in the Far-East whereas WCT is favoured in the Middle East and Eastern Europe [9].

The concept of cupping is to let out "bad blood" that is believed to be harmful to the body and this will also improve the flow of Qi, which is believed to be the life energy, which travels throughout the body in channels called meridians [8]. There are five different explanatory models for the action of cupping [1, 16]:

- 1) Humoural pathology based on the concept that blood is one of the four vital fluids that explain human activity, health and illness.
- 2) Withdrawal of superficial 'bad blood'. According to this model, the disease is in 'bad blood' so when 'ill substances' are drained away, the disease leaves.
- 3) Healthful effects of blood extraction. Lessening the total blood volume improves the quality of the remaining blood.
- 4) Counter-irritation model that irritation of the body surfaces relieves pressure of underlying structures. This action may be related to physiological effects of the nervous system.

5) The combination of cupping and acupuncture model by assuming that stimulation of specific points on the skin harmonizes the control systems of the body.

In Iraq, only medically qualified personnel or related health care providers are allowed to provide health care to patients. Most indigenous healer professional are, therefore, illegal.

Our study showed that back pain in males (29.4%) and frozen shoulder in female (30.3%) were the commonest complaints among patients having cupping therapy. This concludes that cupping therapy has a role in pain control. Farhadi et al. [17] found that wet cupping therapy was associated with clinically significant pain relief at 3-month follow-up. Wet cupping therapy improved lower back pain intensity, pain-related disability, and medication use ( $p < 0.01$ ) than the control group. In the US, acupuncturists use cupping therapy to treat 20% of all low back pain patients [18]. Cupping is believed to stimulate pain receptors which lead to increase the frequency of impulses, therefore ultimately leading to closure of the pain gates and hence pain reduction [19].

Skin diseases presented in 5.9% of our cases. Five cases (4.2%) were males (Two cases of psoriasis, Two cases of vitiligo and one case of eczema) and one case of psoriasis (3%) in females. Cupping was used widely to treat skin conditions [10, 12, 20]. Cupping has been used in the treatment of vitiligo where blister roofs induced by cupping were able to regment vitiliginous patches in 80% of the patients with good coloring match, without any cosmetic disfigurement at the donor sites [21]. In another study [22], cupping and Chinese herbs treatment for vitiligo were more effective than medical treatment ( $p < 0.05$ ). Similar findings were found in neurodermatitis eczema and psoriasis, acne, post herpetic neuralgia, atopic dermatitis, urticaria and pruritis [23, 24, 25, 26, 27, 28].

Cups in our study were commonly applied on the back, chest, abdomen, and buttock where good bulk of muscles were present. This was the approach in other studies [3, 5]. Patients complained from tingling sensation and tightness as a result of bloodletting and suction. The echymosis and bleeding were the common immediate skin changes in cupping. This

results from breaking the superficial blood vessels in the papillary dermis under the negative pressure creating the distinctive circular cutaneous lesions. The after-effects of cupping often include erythema, edema, and ecchymosis in a characteristic circular arrangement. These bruises may take several days to several weeks to subside [3, 5].

Late skin changes after 30 days included scars in 6% and hyperpigmentation in 4 %. This was also the case in other studies [3, 5]. Bruises can stay until 30 days especially if the cups were left for long period of time. There was no major side effects apart from slight discomfort which is technique related, patients may feel warm due to hyperemia and vasodilatation. Slight sweating and headache has been reported as well. Burns is not a common side effect of cupping nowadays because plastic cups and mechanical suction are used instead of the old practice of using alcohol-soaked cotton at the base of brass, steel, or glass cups, which was subsequently lit on fire [29, 30]. Serious adverse effects were not reported in any of the trial publications [11]. Suction bullae has been reported in prolonged cupping [31, 32]. In children, this should raise the suspicion of child abuse [33].

Histological changes in epidermis may result from disruption of epidermal adhesion and vasodilatation which lead to transudation of fluid. Similar changes happen in the dermis with dermal bleeding and oedema as a result of increased blood flow to the cupped region (hyperaemia).

### Conclusion

Cupping is a common alternative therapy for several diseases. It is a safe, non-invasive, and inexpensive. Dermatologists should recognize the unique morphology resulting from this procedure. Cupping is not associated with serious adverse events if done in fully sterile condition. Most of the local skin changes subside within few weeks. Histological changes in the skin results from vasodilatation and oedema with no cellular infiltrate.

### References

1. Oumeish OY. The philosophical, cultural, and historical aspects of complementary, alternative, uncon-

ventional, and integrative medicine in the old world. Arch Dermatol 1998; 134: 1373-1386. PMID: 9828871

2. Gao LW. Practical Cupping Therapy [in Chinese]. Beijing: Academy Press; 2004.
3. Stux G, Pomeranz B. Basic of acupuncture, fourth revised ed. Springer, Heidelberg, Germany. 1998.
4. Xue CC, O'Brien KA. Modalities of Chinese medicine. In: Leung P-C, Xue CC, Cheng Y-C (Eds), Comprehensive Guide to Chinese medicine. World Scientific. Singapore 2003; 19-46.
5. Yoo SS, Tausk F. Cupping; east meets west. Int J Dermatol 2004; 42: 664-665. PMID: 15357746
6. Chirali IZ. Traditional Chinese Medicine Cupping Therapy, 6<sup>th</sup> Edition. Churchill Livingstone 1999.
7. Lipton RB, Scher AI, Steiner TJ, Bigal ME, Kolodner K, Liberman JN. Patterns of health care utilization for migraine in England and in the United States. Neurol 2003; 60: 441-448. PMID: 12578925
8. Cao H, Han M, Li X, Dong S, Shang Y, Wang Q, Xu S, Liu J. Clinical research evidence of cupping therapy in China: a systematic literature review. BMC Complement Altern Med 2010, 10:70. PMID: 21078197
9. Hajar. Hajar Albinali, Traditional Medicine Among Gulf Arabs Part II - Blood Letting 2004; Vol 5: No.2.
10. Koo J, Arain S. A Traditional Chinese Medicine for the Treatment of Dermatologic Disorders. Arch Dermatol 1998; 134: 1388-1393. PMID: 9828872
11. Esenberg DM, Davis RB, Ettner SL et al. Trends in alternative medicine use in the United States. JAMA 1998; 280: 1569-1575.
12. Ernst E, Pittler MH, Wider B, Boddy K. Acupuncture: its evidence-base is changing. Am J Chin Med 2007; 35: 21-25.
13. Salomonsen LJ, Skovgaard L, Sørensen C, Nyborg L, Launsø L, Fønnebø V. Use of complementary and alternative medicine at Norwegian and Danish hospitals. BMC Complementary and Alternative Medicine 2011; 11: 4. PMID: 21244655
14. AlBedah A, Khalil M, Elolemy A, Elsubai I, Khalil A. Hijama (cupping): a review of the evidence. Focus Altern Complement Ther 2011; 16: 12-16.
15. Tham LM, Lee HP, Lu C. Cupping: From a biomechanical perspective. J Biomechan 2006; 39: 2183-2193. PMID: 16126216
16. Vaskilampi T, Hänninen O. Cupping as an indigenous treatment of pain syndromes in the Finnish cultural and social context. Sot Sci Med 1982; 16: 1893-1901. PMID: 7178935
17. Farhadi K, Schwebel D, Saeb M, Choubsaz M, Mohammadi R, Ahmadi A. The Effectiveness of Wet-cupping for Nonspecific Low Back Pain in Iran: A Randomized Controlled Trial. Complement Ther Med 2009; 17: 9-15. PMID: 19114223
18. Sherman KJ, Cherkin DC, Hogeboom CJ. The diagnosis and treatment of patients with chronic low-back pain by traditional Chinese medical acupuncturists. J Altern Complement Med 2001; 7: 641-650. PMID: 11822612
19. Ahmadi A, Schwebel DC, Rezaei M. The efficacy of wet-cupping in the treatment of tension and migraine

- headache. Am J Chin Med 2008; 36: 37-44. PMID: 18306448
20. Chen CJ, Su Yu H. Acupuncture, electro stimulation, and reflex therapy in dermatology. Dermatol Ther 2003; 16: 87-92. PMID: 12919109
21. Awad S S. Chinese Cupping: A Simple Method to Obtain Epithelial Grafts for the Management of Resistant Localized Vitiligo. Dermatol Surg 2008; 34: 1186-1193. PMID: 18537996
22. Shu-qin Z, Jie C. Treatment of 30 Cases of Vitiligo by Cupping Method plus External Application of Chinese Herbs. J Acupunc Tuina Sci 2004; 2: 42-43.
23. Zhang Y, Zhou JW, Huang S et al. Observation on the therapeutic effect of a red-hot needle therapy combined with blood-letting puncture and cupping for treatment of neurodermatitis. Zhongguo Zhen Jiu 2007; 27: 252-254. PMID: 17585666
24. Iliiev E, Broshtilova V. Traditional Chinese Medicine and psoriasis vulgaris. Sem Integ Med 2003; 1: 145-150.
25. Zhang H, Qu X: Advances in experimental studies on treatment of psoriasis by TCM. J Trad Chin Med 2002; 22: 61-66. PMID: 11977526
26. Jin MZ, Xie ZQ, Chen XW, Chen DX, Chen DP. Observations on the efficacy of blood-letting puncture and cupping in treating middle-aged and senile herpes zoster [in Chinese]. Shanghai J Acupunc Moxibust 2008; 27: 20-21.
27. Luo SX, Xie YL, Ji DY: Clinical observation of wet cupping therapy combined with western medications on herpes zoster [in Chinese]. Chinese J Misdiag 2008; 18: 1579-1580.
28. Chen D, Jiang N, Cong X. 47 cases of acne treated by prick-bloodletting plus cupping. J Tradit Chin Med 1993; 13: 185-186. PMID: 8246588
29. Iblher N, Stark B. Cupping treatment and associated burn risk: a plastic surgeon's perspective. J Burn Care Res 2007; 28: 355-358. PMID: 17351459
30. Kose AA, Karabagli Y, Cetin C, et al. An unusual cause of burns due to cupping: complication of a folk medicine remedy. Burns 2006; 32: 126-127. PMID: 16046073
31. Tuncez F, Bagci Y, Kurtipek GS, Erkek E. Suction bullae as a complication of prolonged Cupping. Clin Exp Dermatol 2006; 31, 281-305. PMID: 16487127
32. Lee JS, Ahn SK, Lee SH. Factitial panniculitis induced by cupping and acupuncture. Cutis 1995; 55: 217-218. PMID: 7796613
33. Wei Lin C, Tse-Jen JW, Sing Choy C, Tung H-H. Iatrogenic Bullae Following Cupping Therapy. J Altern Complemen Med 2009: 1243-1245. PMID: 19922257